

Endovascular management of extremity arterial trauma

Charles Angotti Furtado de Medeiros^I; Thais Cristina Hatsumura^{II}; Daniel Rassi Gusmão^{III}; Lucas Marcelo Dias Freire^{IV}; Eduardo Faccini Rocha^V; Ana Terezinha Guillaumon^V

^IPhD student in Peripheral Vascular Surgery, Centro de Referência em Cirurgia Endovascular, Universidade Estadual de Campinas (UNICAMP), Campinas, SP, Brazil.

^{II}Resident, Peripheral Vascular Surgery, Centro de Referência em Cirurgia Endovascular, UNICAMP, Campinas, SP, Brazil.

^{III}Resident, Peripheral Vascular Surgery, Centro de Referência em Cirurgia Endovascular, UNICAMP, Campinas, SP, Brazil.

^{IV}Hired physician, Peripheral Vascular Surgery, Centro de Referência em Cirurgia Endovascular, UNICAMP, Campinas, SP, Brazil.

^VProfessor. Head, Peripheral Vascular Surgery, Centro de Referência em Cirurgia Endovascular, UNICAMP, Campinas, SP, Brazil.

Correspondence

J Vasc Bras. 2008;7(1):56-61.

ABSTRACT

Treatment of arterial traumatic injuries is usually performed with conventional revascularization techniques. However, vascular injuries can increasingly be repaired efficiently through minimally invasive procedures. We report four cases of extremity arterial trauma treated by endovascular techniques in a reference center. All patients showed satisfactory development over a 15-month follow-up. We suggest that endovascular therapy is a promising alternative to surgery for selected patients with extremity arterial trauma.

Keywords: Vascular trauma, pseudoaneurysm, ischemia, emergency treatment.

RESUMO

Geralmente o tratamento das lesões arteriais traumáticas é realizado com técnicas tradicionais de revascularização. Cada vez mais, porém, as lesões vasculares podem ser corrigidas com eficiência

por meio de procedimentos minimamente invasivos. Nós descrevemos quatro casos de trauma arterial dos membros que foram tratados por técnicas endovasculares num centro de referência. Todos os pacientes evoluíram satisfatoriamente durante o seguimento de 15 meses. Nós sugerimos que o tratamento endovascular é uma alternativa promissora em relação à cirurgia para pacientes selecionados com trauma arterial dos membros.

Palavras-chave: Trauma vascular, pseudo-aneurisma, isquemia, tratamento de urgência.

Introduction

Traumatic arterial lesions with acute limb ischemia are usually repaired by traditional revascularization techniques.¹⁻⁴ In general, limb amputation rate ranges according to lesion mechanism, whether penetrating or blunt, between 10 and 30%, respectively. To improve that rate, it is necessary to develop new techniques for circulation restoration.

Due to its minimally invasive character, the endovascular surgery can have some advantages compared to the conventional treatment in selected cases of vascular trauma. Next, we report on four cases of limb arterial trauma that were attended at the Emergency Room of Hospital de Clínicas da Universidade Estadual de Campinas and successfully submitted to endovascular treatment by the peripheral vascular surgery team.

Case description

Case 1

A 31-year-old male patient was victim of penetrating bullet injury (BI) with entrance hole (EN) in the right subscapular region and exit hole (EX) in the right infraclavicular region. Physical examination: stable, no signs of ischemia, audible systolic murmur in the right infraclavicular region. Duplex scan confirmed diagnostic hypothesis of right axillary artery pseudoaneurysm. The patient was submitted to digital angiography through femoral approach and repair of axillary artery lesion by placement of a JOMED[®] balloon stent graft through retrograde brachial approach at the same time (Figures [1](#) and [2](#)).

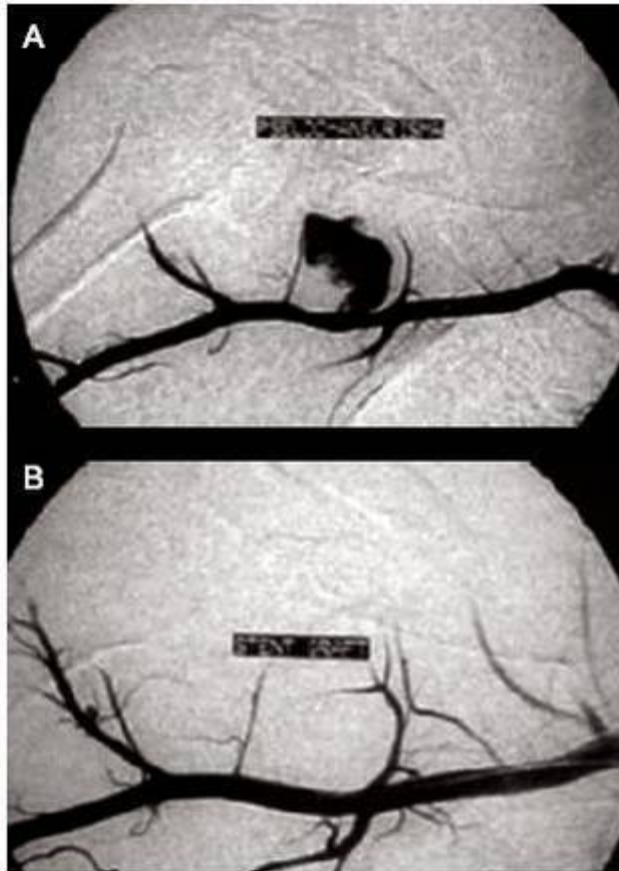


Figure 1 - Digital angiography in case 1: A) preoperative period, right axillary artery; B) postoperative period, stent graft repair

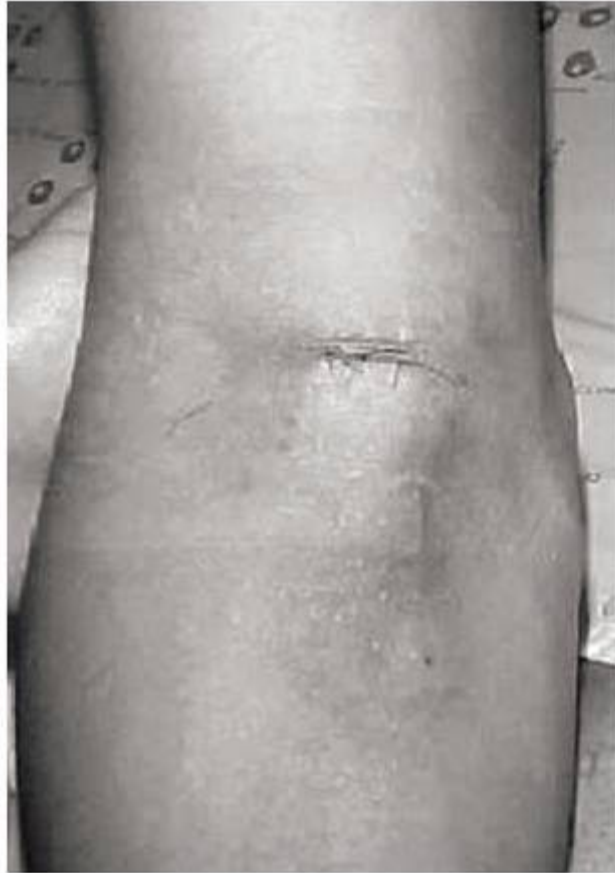

Figure 2 - Photograph of retrograde brachial access in case 1

Case 2

A 22-year-old male patient was victim of multiple penetrating BI, one of them with EN in the left scaphoid region and EX in the lateral aspect of the left arm. Physical examination: stable, with signs of ischemia in the left upper limb and brachial-brachial index = 0.5. Duplex scan confirmed left axillary artery thrombosis (Figures [3](#) and [4](#)). The patient was submitted to digital angiography through femoral approach, axillary artery recanalization and lesion repair by placement of a JOMED[®] balloon stent graft.

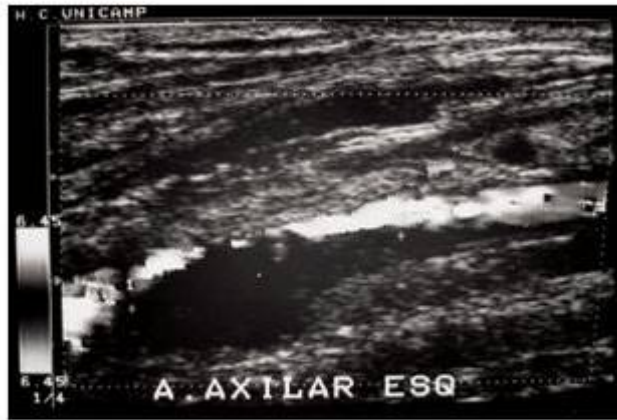

Figure 3 - Doppler ultrasound confirming left axillary artery thrombosis in case 2

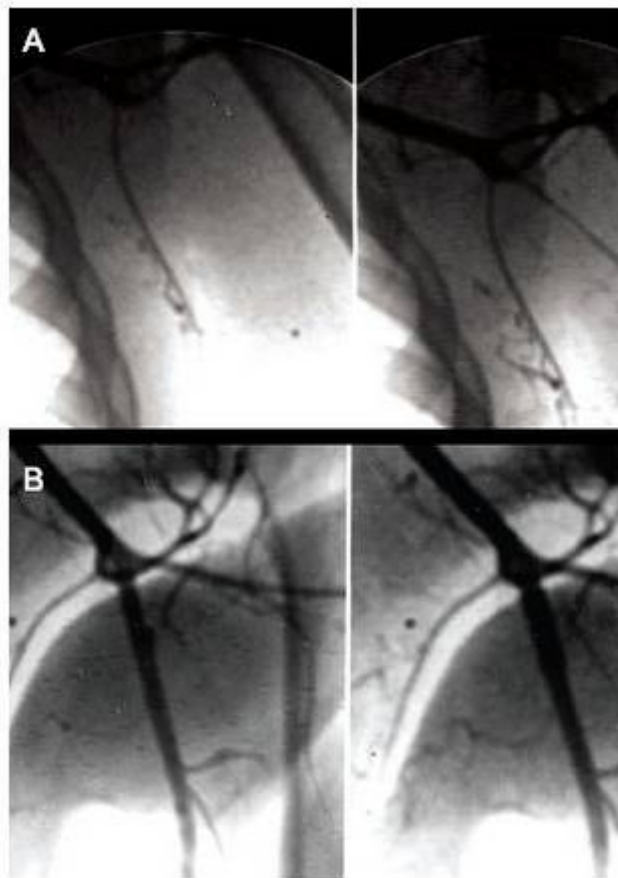


Figure 4 - Digital angiography in case 2: A) left axillary artery recanalization using a guide wire; B) control after stent graft

An 18-year-old male patient was victim of a penetrating BI with EN in the left cubital fossa and EX in the left axillary crease. Physical examination: stable, with signs of ischemia in the left upper limb and brachial-brachial index = 0.6. The patient was submitted to digital angiography through femoral approach, axillary artery recanalization and lesion repair by placement of a JOMED® balloon stent graft through retrograde brachial approach at the same time (Figures 5 and 6).

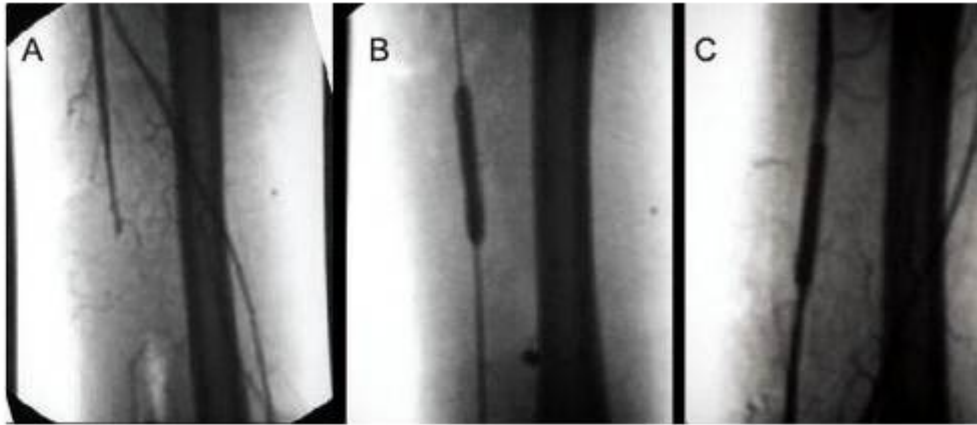


Figure 5 - Digital angiography in case 3: A) left brachial artery thrombosis; B) balloon dilatation of the stent graft; C) final control with discrete difference in diameter

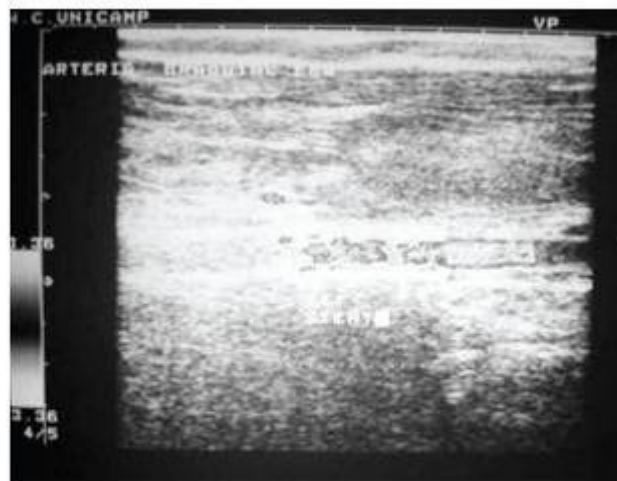

Figure 6 - Doppler ultrasound showing flow after repair of case 3

Case 4

A 44-year-old male patient was victim of motor vehicle accident. Physical examination: stable, with extensive hematoma on the right thigh, absence of popliteal right pulse and absence of Doppler audio signal in distal arteries. Digital angiography was performed through contralateral femoral puncture, confirming total occlusion of the right superficial femoral artery (SFA) in the medial third of the thigh with filling of the popliteal artery above the articular line. The patient was submitted to SFA recanalization and release of OPTIMED® self-expandable stent (Figures 7 and 8).

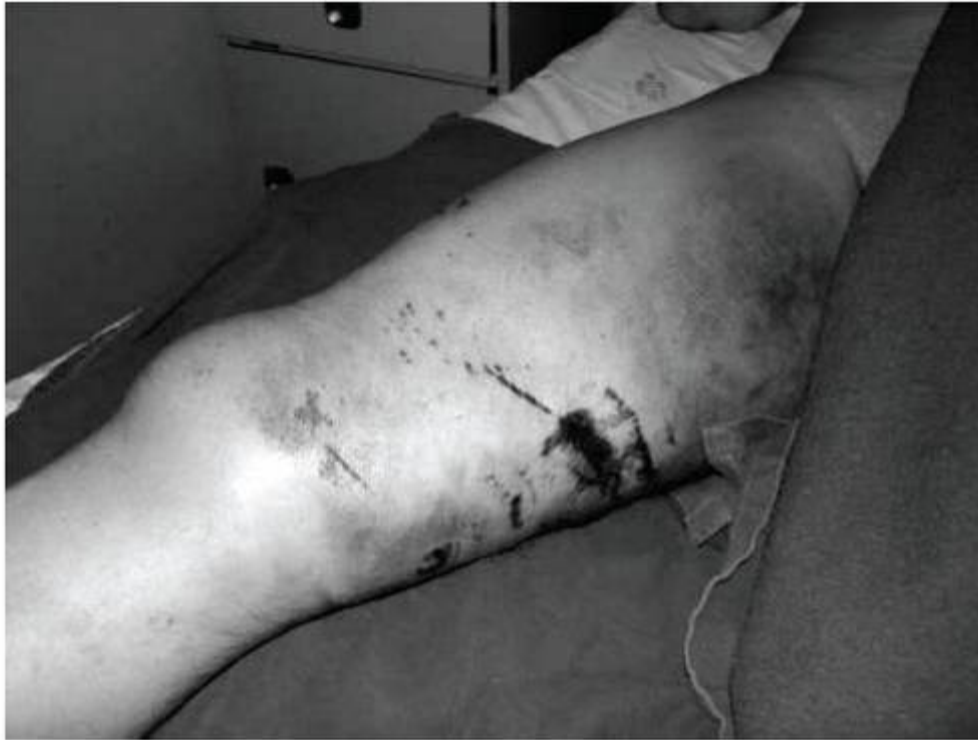

Figure 7 - Photograph of the right thigh in case 4

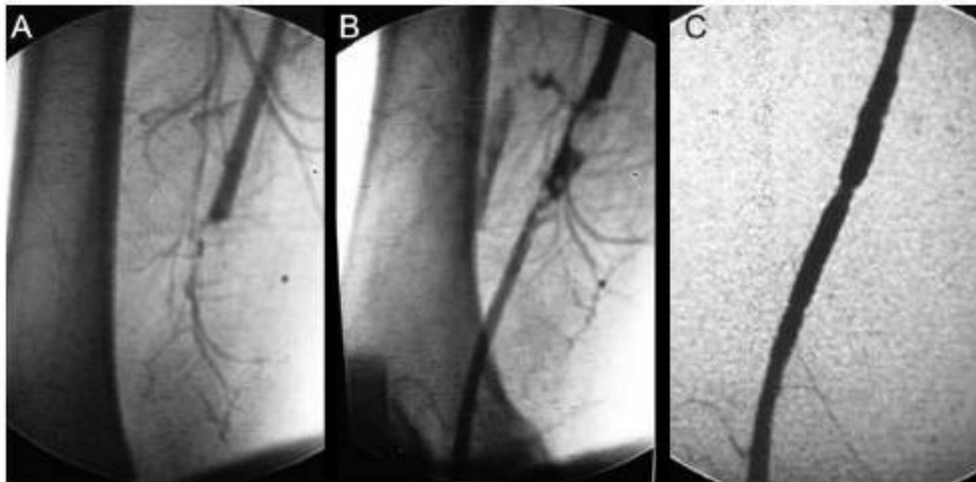


Figure 8 - Digital angiography in case 4: A) right superficial femoral artery thrombosis; B) recanalization using hydrophilic guide wire; C) control after stent release

Discussion

As a result of new options of treatment, care of patients with vascular disease has drastically changed over the past years. Endovascular procedures significantly contributed to most of these changes. Many minimally invasive techniques have also been adapted to multiple trauma patients. This has been well demonstrated in the treatment of solid organ lesions and pelvic fractures, which started being embolized to control hemorrhage.⁵

Nowadays, with the growing advance of endovascular procedures, traumatic lesions of large-caliber arteries can be efficiently repaired, in many cases by endovascular techniques. These procedures seem particularly attractive in blunt trauma, especially in areas between the trunk and extremities, where proximal vascular control is difficult.

Especially in cases of pseudoaneurysm and arteriovenous fistulas, endovascular treatment is of great value. Today, minimally invasive techniques allow repair of acute or chronic lesions, thus avoiding a surgery that is often difficult, at a site where there is change of anatomic structures and intense bleeding.⁶⁻⁸

However, regarding arterial trauma of extremities, therapy becomes a little more challenging. Perhaps for that reason there are few reports on endovascular treatment of trauma in peripheral arteries, whether in lower and upper limbs or in relation to mechanism of lesion, penetrating or blunt.⁹⁻¹⁵

The main advantage of endovascular techniques in these cases is to avoid areas of recent trauma, in which there is a large anatomic distortion in an attempt to expose affected structures to control bleeding and restore blood flow, both essential for limb preservation. As a direct consequence, inadvertent lesions, blood loss and incidence of infections should be much less frequent. Shorter hospitalization time and possibility of treatment using only local anesthesia are also expected.

On the other hand, association with venous and lymphatic lesions is frequent, as well as with bone fractures, soft tissue trauma and neurological lesions. Despite the successful treatment of vascular lesions, neurological lesions determine major functional deficit in up to 40% of cases.¹⁶

So far, there has been no evidence in the literature indicating that endovascular treatment in trauma is better than conventional surgical treatment. Today there is consensus that patients with severe hemodynamic instability or those with major active bleeding have formal contraindication for endovascular treatment. Also, cases of multiple trauma with associated cranial and abdominal lesions should be submitted to conventional surgery, especially if there is contraindication to anticoagulation. Patients with prolonged evolution time (> 6 hours) should also be submitted to open revascularization of the ischemic limb.

In case of emergency, lack of time for planning is a limiting factor. Due to that difficulty, devices chosen were those that could be used, but they also had to be adapted to each situation. All four cases reported above obtained technical success. Mean hospitalization time was 3 days, and during a 15-month follow-up, limb salvation rate reached 100%. Stent patency is easily assessed by a simple physical examination and, if necessary, Doppler ultrasound can be used for confirmation (Figure 6).

It is important to remember that, to obtain such results, there must be proper imaging equipment and a specialized medical team, as well as immediate availability of all the materials that can be used for endovascular repair of any diagnosed lesion. It is also necessary to perform a oriented study to establish the cost-benefit ratio in relation to conventional surgical treatment.

References

1. Deguara J, Ali T, Modarai B, Burnand KG. [Upper limb ischemia: 20 years experience from a single center](#). Vascular. 2005;13:84-91.
2. Huynh TT, Pham M, Griffin LW, et al. [Management of distal femoral and popliteal arterial injuries: an update](#). Am J Surg. 2006;192:773-8.
3. Peck MA, Rasmussen TE. [Management of blunt peripheral arterial injury](#). Perspect Vasc Surg Endovasc Ther. 2006;18:159-73.
4. Vasdekis SN, Kakisis JD, Lazaris AM, Panayiotides JG, Angeli AA, Karkaletsis KG. [Common femoral artery injury secondary to tennis ball strike](#). J Vasc Surg. 2006;44:1350-2.
5. Starnes BW, Arthurs ZM. [Endovascular management of vascular trauma](#). Perspect Vasc Surg Endovasc Ther. 2006;18:114-29.
6. Criado E, Marston WA, Ligush J, Mauro MA, Keagy BA. [Endovascular repair of peripheral aneurysms, pseudoaneurysms and arteriovenous fistulas](#). Ann Vasc Surg. 1997;11:253-63.
7. du Toit DF, Strauss DC, Blaszczyk M, de Villiers R, Warren BL. [Endovascular treatment of penetrating thoracic outlet arterial injuries](#). Eur J Vasc Endovasc Surg. 2000;19:489-95.
8. du Toit DF, Leith JG, Strauss DC, Blaszczyk M, Odendaal JV, Warren BL. [Endovascular management of traumatic cervicothoracic arteriovenous fistula](#). Br J Surg. 2003;90:1516-21.
9. Kember PG, Wood RF, Gaines PA. [Endovascular management of a non-penetrating traumatic axillary artery occlusion](#). Eur J Vasc Endovasc Surg. 1997;14:227-8.
10. Mattox KL, Hirshberg A. Traumatismo vascular. In: Haimovici H, editor. Cirurgia vascular. Rio de Janeiro: Di-Livros; 2000. p. 480-96.
11. Strauss DC, du Toit DF, Warren BL. [Endovascular repair of occluded subclavian arteries following penetrating trauma](#). J Endovasc Ther. 2001;8:529-33.
12. Kuzniec S. Traumatismos vasculares. In: Brito CJ, editor. Cirurgia vascular. Rio de Janeiro: Revinter; 2002. p. 706-20.
13. Aun R, Leão PP. Tratamento dos ferimentos vasculares por métodos endovasculares. In: Brito CJ, editor. Cirurgia vascular. Rio de Janeiro: Revinter; 2002. p. 721-7.
14. Lönn L, Delle M, Karlström L, Risberg B. [Should blunt arterial trauma to the extremities be treated with endovascular techniques?](#) J Trauma. 2005;59:1224-7.
15. Alvarez-Tostado J, Tulsyan N, Butler B, Rizzo A. [Endovascular management of acute critical ischemia secondary to blunt tibial artery injury](#). J Vasc Surg. 2006;44:1101-3.
16. Johnson SF, Johnson SB, Strodel WE, Barker DE, Kearney PA. [Brachial plexus injury: association with subclavian and axillary vascular trauma](#). J Trauma. 1991;31:1546-50.

 Correspondence:

Charles Angotti Furtado de Medeiros

Rua Izabel Negrão Bertoti, 101/52 Bairro M. Sto. Antônio

CEP 13087-508 – Campinas, SP, Brazil

Tel.: (19) 3256.9771

Email: drcharlesangotti@hotmail.com

Manuscript received January 8, 2008, accepted January 24, 2008.